



Differentiating Cardiac vs
Noncardiac Chest Pain in the
Primary Care setting

Randy Minton MD FACC
PLUMBER



Disclosures: None

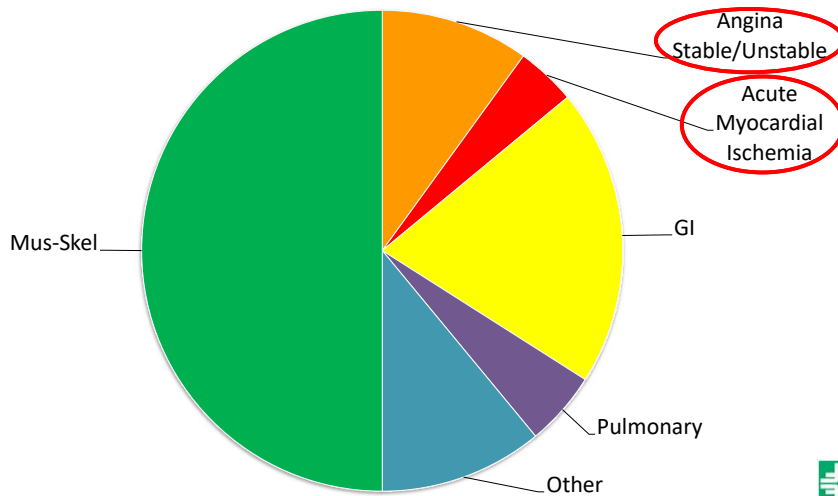


Clinic Chest Pain Etiologies

- Musculoskeletal
- Gastrointestinal
- Pulmonary
- Other
- Cardiovascular



Clinic Chest Pain Etiologies



Clinic Chest Pain Musculoskeletal Etiology

- Cervical disc disease / Neuropathic pain
- Fibrositis/Fibromyalgia → Trigger points
- Herpes zoster (before rash)
- Sternoclavicular arthritis → Finger tip diagnoses
- Costochondritis → Finger tip diagnoses
- Rib fracture - History



Clinic Chest Pain GI Etiology

- Esophageal
 - Esophagitis/Reflux
 - Spasm
 - Rupture
- Peptic ulcer disease
 - Nonperforating
 - Perforating
- Biliary
 - Cholangitis
 - Cholecystitis
 - Choledocholithiasis
 - Colic
- Pancreatitis

Proton pump inhibitor
Antacid PRN

TAKE BEFORE EVENING MEAL
NOT BEDTIME

If it hurts when you do that...



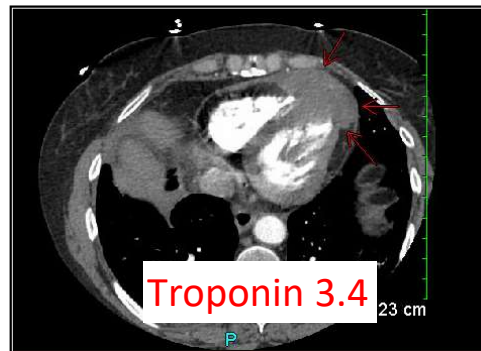
Clinic Chest Pain Pulmonary Etiology

- Pleuritis - Pain with inspiration
- Pneumonia → CXR
- Pulmonary embolus → CTA
- Tension pneumothorax → CXR



Clinic Chest Pain Other Etiologies

- Affective disorders (eg, depression)
- Anxiety / Panic / Hyperventilation
- Malignancy



Clinic Chest Pain Other Etiologies

- Affective disorders (eg, depression)
- Anxiety / Panic / Hyperventilation
- Malignancy
- Somatoform disorders
- **Other**



Clinic Chest Pain Cardiovascular Etiologies

- Nonischemic
 - Pericarditis
 - Myocarditis
 - Aortic dissection
 - Penetrating Aortic Ulcer (PAU)
- Ischemic
 - Stable
 - Unstable



Clinic Chest Pain

Acute Pericarditis

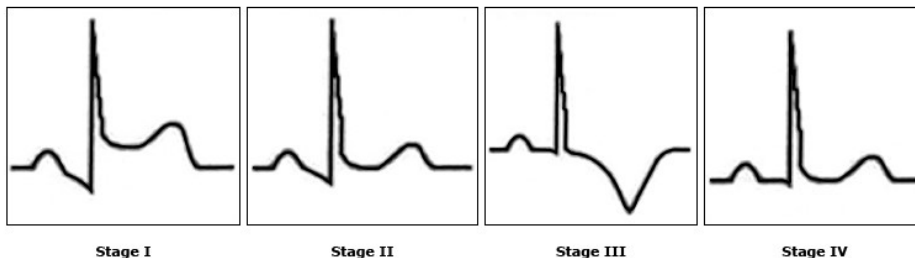
- Fever
- Pain decreases leaning forward
- Friction rub... **sometimes**
- Cardiac enzyme elevation
- ECG diffuse ST elevation



Clinic Chest Pain

Acute Pericarditis

- ECG ... **variable**



Stage I

Stage II

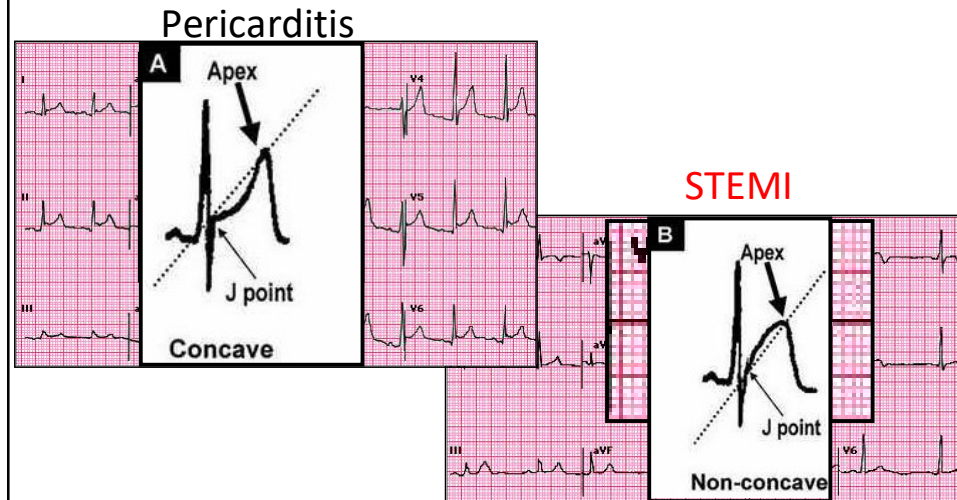
Stage III

Stage IV



Clinic Chest Pain

Acute Pericarditis



Clinic Chest Pain

Acute Pericarditis

Outpatient vs Inpatient

- Fever > 100.4
- Subacute course
- Hemodynamic compromise
- Large pericardial effusion
- Anticoagulated
- Acute trauma
- Elevated troponin c/w myopericarditis

ADMIT



Clinic Chest Pain

Acute Pericarditis

Treatment options for idiopathic/viral pericarditis

- Ibuprofen 600-800 mg TID
- Aspirin 650-1000 mg TID
- Indomethacin 25-50 mg TID

Taper after resolution of symptoms
over 2 week period



Clinic Chest Pain

Myocarditis

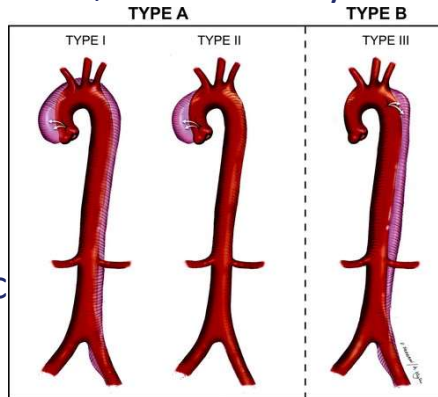
- *Variable* presentation
- Regional ST elevation even with ST depression and can be difficult to distinguish from a STEMI
- CP/Excessive fatigue
- Cardiac enzyme elevation
- CHF
- Cardiac arrest
- Definitive diagnosis: Endomyocardial biopsy



Clinic Chest Pain

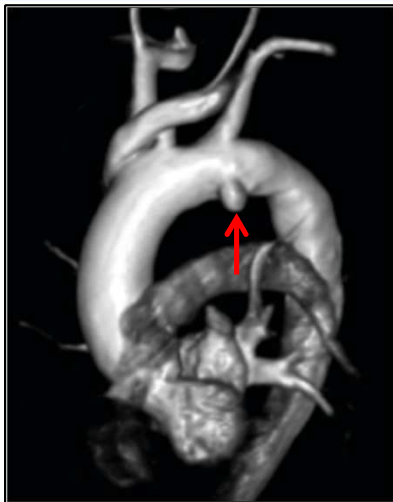Aortic dissection

- Marfan, family hx, AV disease, aortic aneurysm
- Acute onset
- Tearing/stabbing pain
- Interscapular
- Unequal arm BPs
- Murmur – New/diastolic
- ECG possible STEMI



Clinic Chest Pain

Penetrating Aortic Ulcer (PAU)




Clinic Chest Pain Stable Angina

- DEFINITION: CP w/ activity or emotional stress
- QUALITY: Sharp/dull/pressure/squeezing
****Not reproducible w/ palpation****
- RADIATION: Neck/jaw/arm/back
- CONTEXT: Walking/stairs/exercise/other



Clinic Chest Pain Risk Stratification



Clinic Chest Pain Unstable Angina

- DEFINITION: CP of recent onset, at rest or episodes lasting > 20 minutes



Clinic Chest Pain STEMI

